

Case report

Missed Gall Stone Masquerading as Recurrent Retroperitoneo-Cutaneous Fistula

Siba Narayan Padhi ^{*1}, Asuri Krishna², Om Prakash Prajapati³, Virender Kumar Bansal⁴

^{*1}Junior Resident, Department of Surgical Disciplines, All India Institute of Medical Sciences.

²Additional Professor, Department of Surgical Disciplines, All India Institute of Medical Sciences.

³Associate Professor, Department of Surgical Disciplines, All India Institute of Medical Sciences.

⁴Professor, Department of Surgical Disciplines, All India Institute of Medical Sciences

***Corresponding author:** Siba Narayan Padhi, Junior Resident, Department of Surgical Disciplines, All India Institute of Medical Sciences

Received: 12-09-2022

Accepted: 16-09-2022

Published: 29-09-2022

Copyright

© 2022 Siba Narayan Padhi

OPEN ACCESS

Summary:

Spillage of gallstones is a frequent complication of laparoscopic cholecystectomy, occurring in 32% to 40% of all cases [1]. In up to a third of these cases, stones are not retrieved. Although the incidence of early and late complications of lost gallstones is low (0.08-0.3%), majority of these cases present as intra-abdominal abscess requiring drainage and only few presents with persistent discharging peritoneo-cutaneous fistula [2,3]. We present a rare case of a patient who presented to our tertiary care centre 5 years after laparoscopic cholecystectomy with recurrent discharging sinus in right lumbar region with history of multiple surgical interventions. Radiological studies showed well circumscribed fistulous tract extending from skin to retroperitoneal space and anteriorly up to parenchyma of segment VI of liver with retained gall stones. He underwent Exploration & excision of the sinus tract with removal of the gall stones. He had an uneventful post-operative course with no recurrence of symptoms until one and half years of follow up.

Background:

In the current era of minimally invasive surgery, laparoscopic cholecystectomy has become the gold standard for the surgical treatment of symptomatic gallstones. However, some complications such as biliary tract injuries and intraoperative spillage of stones are more common during laparoscopic

cholecystectomy as compared to open procedure. Although the rate of common bile duct injury has decreased because of better training and more experience of surgeons, but gallbladder perforation and gallstone spillage remain a common problem occurring in 32% to 40% of all cases [4]. Gallstone spillage can

occur during an open cholecystectomy, but in this procedure, stones can be removed by thorough irrigation under direct vision. In laparoscopic procedure, however, various factors such as limited working area and surgeon's low experience may lead to failure in spilled gallstone retrieval. Although the incidence of early and late complications of lost gallstones is low (0.08-0.3%), majority of these cases present as intra-abdominal abscess requiring drainage and only few presents with persistent discharging peritoneo-cutaneous fistula. We report a rare case of a male patient presenting with recurrent Retroperitoneo-Cutaneous fistula 5 years after a laparoscopic cholecystectomy done for symptomatic cholelithiasis.

Case Presentation:

A 44-year-old diabetic patient presented to the surgical outpatient with a non-healing recurrent discharging sinus in the right flank. He had undergone laparoscopic cholecystectomy for symptomatic cholelithiasis 5 years back at a community level hospital. He had an uneventful post operative course. However, the records of the index surgery were not available. Following the index procedure, he was apparently alright for a year and subsequently developed a swelling in the right flank associated with fever. He was diagnosed to have an abscess and underwent incision and drainage along with a course of antibiotics. After an initial period of recovery, the abscess recurred and he underwent multiple sittings of drainage and culture appropriate antibiotics. He was even started on empirical anti tubercular treatment which he took for 9 months with no avail.

A year later he underwent a diagnostic sinoscopy with exploration and excision of sinus tract and 12th rib for the persistent discharging sinus in view of suspicion of underlying osteomyelitis of 12th rib; after which there was temporary relief of symptoms for 4 months. However, the symptoms re occurred and after another year he underwent a Diagnostic Laparoscopy with curettage of fistulous tract and laser ablation of the tract. Tissue sent for histopathology showed Inflammatory tissue without any granuloma. During this protracted course he had undergone multiple imaging (CECT Abdomen, CT Sinogram and MRI) and FNAC of the swelling which had revealed spindle cells. Pus for

AFB staining, culture, Gene Xpert and PCR for Tuberculosis were all negative.

On presentation he was a morbidly obese male with a BMI of 39.1 kg/m². On Examination, a 1x1 cm sinus with pus discharge was seen in the right lumbar region with indurated margins. Scar marks of the previous surgeries were seen (Figure 1).

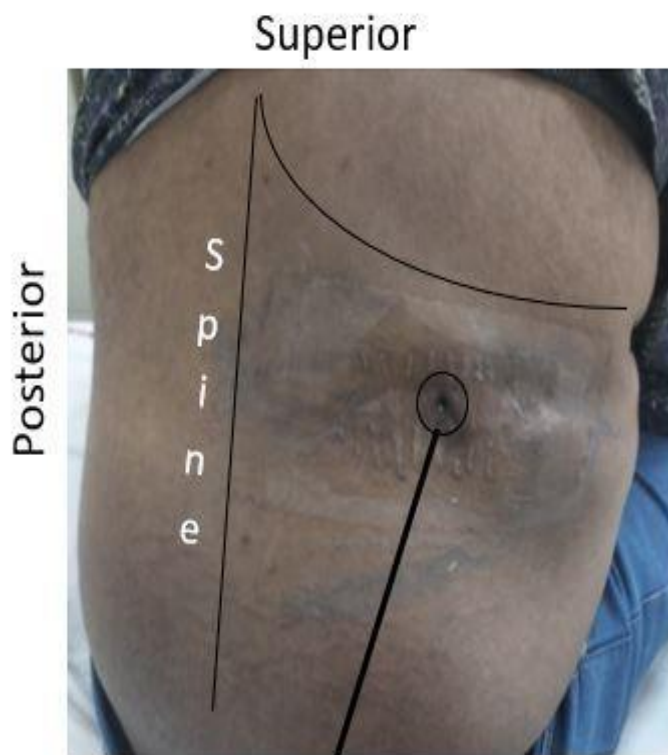


Figure 1 – Sinus tract in right lumbar region with scar marks of previous surgeries

Investigations:

His haematological and biochemical profile were within normal limits. His blood sugars were fairly controlled with a HbA1c of 7.0. His previous scans were reviewed and a fresh MRI was done. The MRI revealed a well circumscribed thick-walled fistulous tract extending from skin to retroperitoneal space and anteriorly up to parenchyma of segment VI of liver with filling defects suggestive of missed spilled gall stones (Figure2).

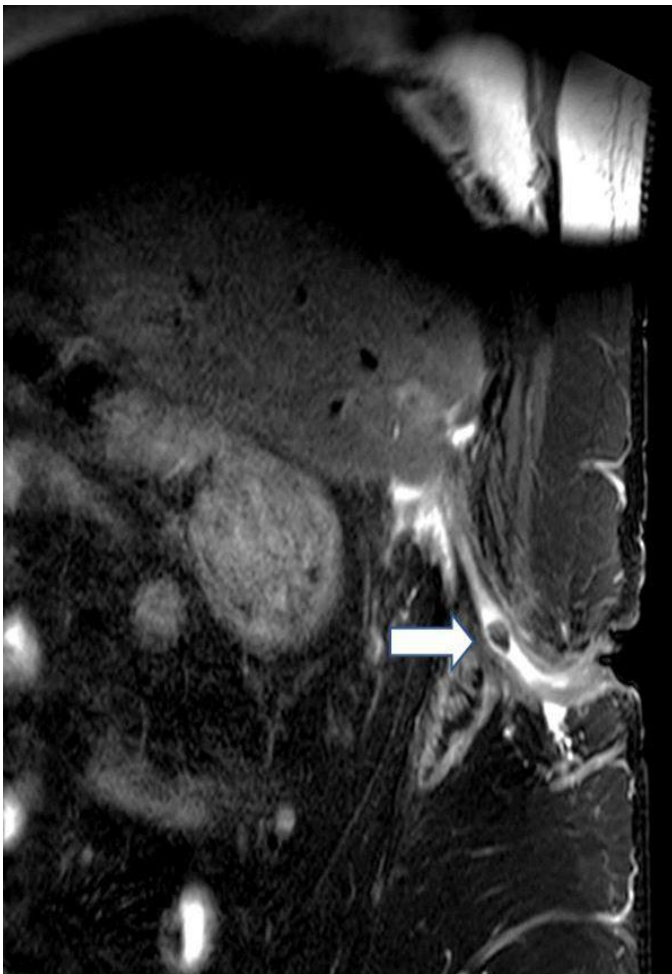
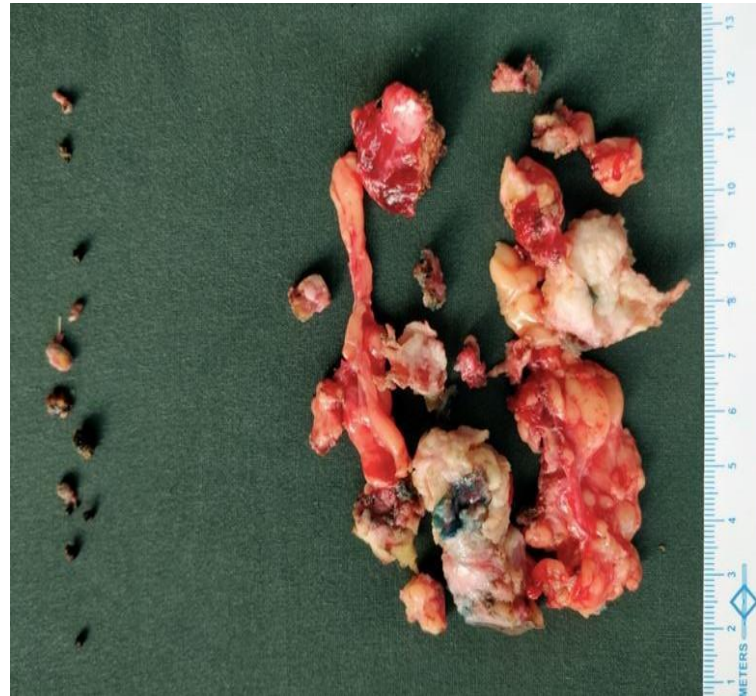


Figure 2 - T2 weighted sagittal image of abdomen showing the fistulous tract in its entire extent reaching from the Segment VI of Liver with surrounding heterogenous collection & inflammation with well defined walls of the fistulous tract. Arrow showing well defined round discrete T2 hypointense content within the tract suggesting a retained gall stone.

Treatment:

After imaging showing the presence of retained gall stones, a final diagnosis of retro peritoneal cutaneous fistula with missed gall stones was made and he was subsequently planned for surgical exploration. The surgery was performed under GA with the patient in a left lateral decubitus position. Prior to surgery, methylene blue dye was injected through sinus tract. The abdomen was entered via a right subcostal incision. Dense adhesions were noted between the liver and lateral parietal wall. Methylene blue stained fibrosed sinus tract seen extending to segment VI of liver. Multiple small stones were seen along the tract and at the adhered liver segment. All visualised stones were

retrieved after through exploration (Figure 3). Entire tract along with fibrosed tissue was excised followed by copious irrigation. The excised sinus tract was left open.



Outcome And Follow-Up:

Patient had an uneventful postoperative period with healthy healing wound and was discharged on post-operative day 10 and the wound was allowed to heal by secondary intention. Histopathology of the sinus tract showed fibrocollagenous sinus wall lined by inflammatory granulation tissue with foreign body type giant cells with no granuloma.

Patient has been doing well for the last one and half years and has no recurrence of symptoms till date.

Discussion:

Bile and gallstone spillage during laparoscopic cholecystectomy is more common than during open cholecystectomy, occurring in 32% to 40% of laparoscopic procedures. Certain situations such as an acutely inflamed gall bladder, dense adhesions making a difficult dissection, and a tense, distended gallbladder that has not been decompressed lead to higher risk of gall bladder perforation during laparoscopic cholecystectomy [1,5]. Spilled stones are also caused by the slipping of the cystic duct clip or the tearing of the gallbladder while it is retrieved from the port site [6].

Although lost gallstones were initially considered innocuous, it is

now recognised that they can be a small but significant source of postoperative morbidity (0.1 to 6%). Zehetner et al reported that 8.5% of these lost gallstones will lead to a complication [7].

The most frequently reported complications are intra-abdominal abscesses and abscesses of the abdominal wall, followed by subhepatic and subphrenic abscesses. Another common complication is fistula formation, which occurs across a broad spectrum, ranging from fistulas of the skin or umbilicus to colocutaneous or colo vesical fistulas with an estimated incidence of 0.3% to 2.9%. In laparoscopic cholecystectomy, the pneumoperitoneum and irrigation of the peritoneal cavity can disperse spilled gallstones in different locations such as the subhepatic space, right subphrenic space, port sites, right flank, or retroperitoneum. In addition, stones can migrate to the dependent areas such as the pelvis or pass through the diaphragm. These conditions are responsible for various unusual presentations and complications. The risk factors for complications after spilled stones include presence of infected bile, spillage of pigmented gallstones, multiple stones (>15), stone size (>1.5 cm) and old age.

The best way to avoid this complication is to avoid perforating the gall bladder during surgery by meticulous dissection and use of endobags specially for inflamed gall bladders. Even if spillage occurs, all stones should be retrieved immediately rather than waiting till the completion of the procedure. A thorough saline lavage must be given. The clear documentation of the intraoperative gallstone spillage in the medical report is recommended for alerting the clinician in the future to the possibility of stones causing any subsequent problems that might lead to earlier diagnosis.

According to different studies, because of the unknown and somewhat indolent nature of the inflammatory process of gallstones, complications may occur from the immediately postoperative period to a long-time interval of 20 years, and thus they may not be considered in the differential diagnosis of patients with abdominal complaints. A high degree of clinical suspicion is thus required to diagnose this rare complication. Misdiagnosis results in unnecessary and futile interventions adding to the morbidity and inconvenience of the patients as happened in our

case. Majority of the stones can be seen either on an ultrasound or an MRI as in our case. Once a diagnosis has been made, the stones can be retrieved along with drainage of abscess cavities, using either a laparoscopic or open approach.

In conclusion retro peritoneal cutaneous fistula is a rare presentation of missed gall stones and requires a high degree of clinical suspicion. Surgery, either laparoscopic or open remains the cornerstone of treatment

Take Home Messages:

Minimize Gall bladder perforation and spillage

Retrieve all stones if spillage occurs

Document spilled stones in medical records (*Out of sight but kept in mind*)

Spilled stones may be silent for years

Diagnostic challenge and requires high index of suspicion

PATIENT'S PERSPECTIVE:

I had to undergo multiple imaging procedures and surgical interventions at various centres for the recurrent pus discharge over the last 5 years. Despite all measures, there was recurrence which was a financial as well as mental stress to me. I was then referred to this tertiary care centre where a definitive cause for my disease was found. I underwent surgery for the same and recovered well with no recurrence since the last one and half years. I am very happy now and thankful to all the doctors of this centre.

References:

1. Helme S, Samdani T, Sinha P (2009) Complications of spilled gallstones following laparoscopic cholecystectomy: a case report and literature overview. *J Med Case Reports* 3: 8626.
2. Sathesh-Kumar T (2004) Spilled gall stones during laparoscopic cholecystectomy: a review of the literature. *Postgrad Med J* 80: 77-79.
3. Kumar S (2017) Peritoneo-cutaneous fistula from spilled gall bladder calculus following laparoscopic cholecystectomy. *Clin Case Rep* 5: 720-722.
4. Iannitti DA, Varker KA, Zaydfudim V, McKee J (2006) Subphrenic and Pleural Abscess Due to Spilled Gallstones 4.
5. Bhati CS, Tamijmarane A, Bramhall SR (2006) A Tale of

Three Spilled Gall Stones: One Liver Mass and Two Abscesses.

Dig Surg 23: 198-200.

6. Hand AA, Self ML, Dunn E (2006) Abdominal Wall Abscess Formation Two Years After Laparoscopic Cholecystectomy 3.

7. Zehetner J, Shamiyeh A, Wayand W (2007) Lost gallstones in laparoscopic cholecystectomy: all possible complications. Am J Surg 193: 73-78.

*Copyright: ©2022 Siba Narayan Padhi. This is an open- access article distributed under the terms of the Creative Commons Attribution License, which permits unrestricted use, distribution, and reproduction in any medium, provided the original author and source are credited.